FORM COMP AA

(sec Rules 253 (c)] 254 (c) (iii), 254 (80 255 (1) (iv))

REPORT ABOUT THE MOTOR VEHICLES ACCIDENTS

1	Name of the Police Station	Ardhapur Dist. Nanded
2	CR.NO./TAR No./SDE No.	251/2019 U/s 279, 304(a) of IPC
3	Date, Time and Place of the accident.	02/10/2019 at 1345Ardhapur to Tamsa Road by pass chouk Ardhapur Tq Ardhapur Dist Nanded
4	Name of the Injured / Deceased	1) Balaji Gunaji Kokate age 42 years 2) Pundlik Damaji Shinde age 55 yers r/o Tirkaswade tq.Mudkhed Dist Nanded
5	Name of Hospital to Which he/she was removed	Govt. Hospital Nanded
6	Number of vehicles and type of the vehicle	MH 35 K 3690 Truck
7	Name and address of the Driver of the vehicle with particulars or Driving License of the said Driver and the address of the Issuing Authority of the said Driving License. The number of Badge in case of Public Service Vehicle and the address of the Issuing Authority of the said Badge.	Sureshkumar Kapurchad Dhomne age 40 years r/o Mundirpar tq.dist.Gondia MH 35 201000044790 RTO Gondia
8	Name and Address of the Owner of the vehicle as it stands on the date of the accident.	Surjeetkumar Tejendrasing Chhabda r/o kudwa line ganj eard Gondia tq.dist.Gondia
9	Name and address of the insurance Company with whom the vehicle was insured and the Divisional office of the said insurance Company.	Chola MS General Insurance Copmany
10	Number of Insurance Policy/Insurance Certificate and the date of Validity of the insurance Policy/Insurance Certificate.	3379/01969794/000/01 01/03/2020
11	Action taken if any and the result there of	An offence has been registered against the accused. After completion of investigation Charge-sheet has been submitted.

Inspector of Police
Police Station Ardhapur
Dist. Nanded

अर्धापूर - 251

दिनांक 02/10/2019

जबाब

मी, श्रीपती शेवंतराव येळणे वय 30 वर्षे, व्यवसाय- चालक रा. तिरकसवाडी ता. मुदखेड जि. नांदेड मो.नं. 8007593860

समक्ष पो.स्टेला हजर येवून जबाब देतो की, मी वरील ठिकाणचा राहणारा असून मला दोन मामा असून नामे माझा मोठा मामा नामे बालाजी गुणाजी कोकाटे हा आचारी काम करतो व छोटा मामा रामराव हा शेती करतो.

आज दि. 02/10/2019 रोजी दुपारी पावणे दोन वाजताचे सुमारास मी व शिवाजी अंबाजी खुपसे, गजानन चिंतामण येळणे असे मिळून माझी कार क्र. MH-13-BN-2011 ने अर्धापुर येथून तिरकसवाडीकडे जात आसताना माझा मोठा मामा बालाजी गुणाजी कोकाटे व आमचे गावातील पुंडलिक दामाजी शिंदे रा. तिरकसवाडी ता. मुदखेड हे त्यांचे स्पलेंडर मोटार सायकल क्र. MH-26-U-5440 ने अर्धापुर ते तामसा रोडने तिरकसवाडीकडे जात असताना बायपास रोड चौकात, ट्रक क्र. MH-35-K-3690 च्या चालकाने वारंगा फाटा बायपास कडून येत असताना त्याचे ताब्यातील ट्रक हयगई व निष्काळजीपणे चालवून माझा मोठा मामा चालवित असलेल्या स्पलेंडर मोटार सायकल क्र. MH-26-U-5440 यास जोराची धडक दिली त्यामुळे माझ्या मामा व त्यांची मोटार सायकल ट्रकचे डिझेल टाकीला अडकून ट्रकसोबत फरकटत गेले व रोडचे दुभाजक वट्याला अडकून माझा मामा बालाजी गुणाजी कोकाटे याचे डोक्यास, पायाला, हाताला गंभीर मार लागून जागीच मरण पावला त्यास महामार्ग सुरक्षा पथक वसमत फाटा येथील ऑम्बुलन्सने प्रा. आरोग्य केंद्र, अर्धापुर येथे शवविच्छेदन करणेकामी दाखल केले. तसेच त्याचे सोबत असलेला आमचे गावातील पुंडलिक दामाजी शिंदे याचे डोक्यास मार लागल्याने त्याना उपचारकामी 108 ऑम्बुलन्स ने सरकारी दवाखाना विष्णुपुरी नांदेड नेले असता तेथे डॉक्टरांनी तपासून पुंडलिक दामाजी शिंदे मयत झाला असल्याचे सांगितले सदरची घटना मी प्रत्यक्ष पाहिली असून सदर घटनेस ट्रक क्र. MH-35-K-3690 चा चालक नामे सुरेश कपुरचंद डोमणे वय 41 वर्षे, रा. गोंदिया जि. गोंदिया हा कारणीभुत असून त्यास आम्ही प्रत्यक्ष पाहिले असून त्यास पाहून ओळखतो.

तरी दि.02/10/2019 रोजी पावणे दोन वाजताचे सुमारास बालाजी गुणाजी कोकाटे व पुंडलिक दामाजी शिंदे रा. तिरकसवाडी ता. मुदखेड ह्यांचे मरणास ट्रक क्र. MH-35-K-3690 चा चालक नामे सुरेश कपुरचंद डोमणे वय 41 वर्षे, रा. गोंदिया जि. गोंदिया याने त्याचे ताब्यातील ट्रक हयगई व निष्काळजीपणे चालवून त्यांचे मरणास कारणीभूत झाला आहे म्हणून त्याचेवर योग्य ती कायदेशीर कार्यवाही करावी हि विनंती.

दि 2/10/2019 SD No. 30 वर पेळे 1758 वा. भाग 1 ते 5 गु.र.नं. 251/2019 कलम 279, 304(A) I.P.C. प्रमाणे गुन्हा दाखल करुन पुढील तपास मा. पो.नि. सा. यांचे आदेशाने PSI आगलावे सा. यांचे कडे दिला आहे

ठाणे अंमलदार
पोलीस स्टेशन अर्धापूर

समक्ष

हा जबाब दिला सही

FORM - 1

CRIME DETAILS FORM

घटनास्थळाचा पंचनामा/गुन्हयाचा तपसील नमुना

i) राज्य महाराष्ट्र जिल्हा नांदेड पोलीस स्टेशन अर्धापुर पहीली खबर/कार्यवाही क्रं. 25/2019 दिनांक 02/10/2019

ii) अधिनियम व कलम :- 279, 304 (A) भा.द.वि.

iii) घटनेचे ठिकाण दाखविण्याचे :-

नांव : दीपाली येळगे वडीलाचे/पतीचे नांव : गोपीनाथ येळगे

वय 30 वर्ष, व्यवसाय : चालक जात : मोबाईल नंबर : 8007593860

रा. तिरकसवाडी तालुका मुदखेड जिल्हा नांदेड राज्य महाराष्ट्र

iv) गुन्हयाचा प्रकार (गुन्हयाचे सर्व पध्दतीसह) :-

i) प्रधान शिर्ष :- :- अपघात

ii) प्रधान शिर्षचे वर्गीकरण :-

iii) पध्दती :- MH35 K 3650 चे चालकाने आपले ताब्यातील वाहन ब्यागईने व निष्काळजीपणाने चालवून MH 26 U 5440 चे मो.सा.ला धडक देवून सदर मो.सा.च्या चालक व इतर एक जणाच्या मृत्युस कारणीभुत.

iv) वापरलेली वाहणे :-

v) केलेले वेषांतर/केलेली बतावणी :-

vi) वापरलेली भाषा/बोली भाषा :-

vii) विशेष वैशिष्टय-1 :-

विशेष वैशिष्टय-2 :-

विशेष वैशिष्टय-3 :-

viii) घटनेच्या ठिकाणाचा प्रकार : सदरचे घटनास्थळ हे राष्ट्रीय महामार्ग 161 वरील पर्डी ते बसमतपाटा वाघपाटीवरील नांदेड चौरस्त्याव आहे.

ix) अंतर्भुत मालमत्तेचा प्रकार :-

1)

2)

FC II

5.बळीचा तपशिल (अवश्यक असल्यास स्वतंत्र कागद जोडावा) :-

अ. क्र	संपुर्ण नांव	जन्म तारीख / वय	लिंग	राष्ट्रीयत्व	धर्म	जाती/ जमाती	व्यवसाय	पत्ता	दुखापत गंभीर/ साधी	साधने/ हत्यार
1	2	3	4	5	6	7	8	9	10	11
1)	बानाजी गुणाजी कोकाटे	42 वर्षे	पुरुष	भारतीय	हिंदू		मजुरी	रा. निरकळवाडी ता. मुदखेड जि. नांदेड	मयत	
2)	पुंडलिक दामाजी शिंदे	60 वर्षे	पुरुष	भारतीय	हिंदू		मजुरी	रा. निरकळवाडी ता. मुदखेड जि. नांदेड	मयत	

6. गुन्ह्याचा हेतु :- एमएच 26 के 3640 चे चालकाने आपले ताब्यातील ट्रक धागपीने व निष्काळजीपणाने चालवून एम 26 यु 5440 या स्कुटर मो.सा. ला धडक देऊन सदर मो.सा. चालक बळीला वेळोवेळी त्यांचे मृत्यूस कारणीभूत झाला.

7. चोरीच्या/अतंर्भुत मालमत्तेचा तपशील :-

8. घटनेच्या जागेचे वर्णन :-

आम्हा नमुद पंचाना पोलीस अधीक्षकाचे पोलीसांनी कपीन आणनावे. यांनी कळविले की, नांदेड बायपास चौरस्तावर ट्रक क्र. एमएच 26 के 3640 चे चालकाने वाहन भरधाव बायपास कडून मेन रोडला जाणे ताब्यातील ट्रक धागपीने व निष्काळजीपणाने चालवून एम 26 यु 5440 चे स्कुटर मो.सा. ला ठोकरची धडक देवून

धनाजी गुणाजी कोकाटे व पुंडलिक दायाजी शिंदे रा. निरंजनवाडी
ता. मुदखेड यांचे मृत्युस कारणीभूत ठरल्याबद्दल पो.स्टे. अर्धापूर येथे
गुरन २८१/१७ कलम ३४७, ३०५ (अ) भा.द.वि. प्रमाणे गुन्हा दाखल असून
सदरील गुन्ह्यामध्ये घटनास्थळाच्या खऱ्या परिस्थितीप्रमाणे घटनास्थळ पंचनामा
करायचा आहे आपण पंच म्हणून हजर रहा असे कळविल्यावरून आम्ही
सदर ठिकाणी हजर झालो. यावेळी सदर घटनास्थळावर पोऊपनि कापिन
आमनाथे व ठियादि श्रीपती गोवतराव येळगे हजर असून आमीन
ठियादि यांनी घटनेची मोठ्याने हकीकत सांगून घटनास्थळ दाखविले.
सदरच्या घटनास्थळाचे अवलोकन केले असता सदरचे घटना-
स्थळ हे राष्ट्रीय महामार्ग क्र. १६ वरील पार्डी ते वसमत फाटा बायपास
वरील नामसा बायपास चौरस्त्यावर असून बायपासमधील नामसा ओपोर
कॉलनीवर मो.सा. व ट्रक. टक्कीमध्ये धडकलेल्या ठिकाणापासून अंदाजे
१०ते १५ फुट अंतरापर्यंत रोडवर काळा डिझेल पेन असून सदरील ठिकाण-
पासून २० फुट अंतरावर वसमत फाटा कडे जाणारे रोडचे बाजूला
असलेले त्रिकोणी डिव्हायडर हे रस्त्याकडील बाजूने पूर्णपणे फुटून
सदरील डिव्हायडरमध्ये ट्रकचे पोल्टी टायर घुसून ट्रकचे चाकाचे
आऱ्या पडलेल्या ठिकाणी असून सदरील डिव्हायडर हे जमीनीपासून
अंदाजे दोन फुट उंचीचे असून सदरील डिव्हायडर वर मध्यभागी
आरसीसीचे अंदाजे ७ ते ८ फुट उंचीची पाणी लावलेली
डिझेल पेन असून सदर त्रिकोणी डिव्हायडरवर वाढलेले हिरवे गवत
पण डिझेल पेन असून सदर डिव्हायडरच्या बाजूला मो.सा. पडलेले
डिझेल पेन असून सदर मो.सा. चे सुटे टायर, हँडल हे मो.सा.
चेसिस पासून वेगळे झालेले डिझेल पेन असून तसेच सदरील मो.सा.
चे ऑलरेडी पण गाडीचे चेसिस पासून वेगळे झालेले ठिकाण असून
सदरील मो.सा. ट्रकचे धडकेने पूर्णपणे ठेचलेली असून मो.सा.
उताराचे हे रोडवर पडलेले डिझेल पेन असून सदरील ट्रकच्या

चाकाचे वरा पडलेल्या बाजुस रोडवर रक्ताचे मोठे डाग दिसून येत आहेत.

सदर घटनास्थळाची चतुःसीमा पुढीलप्रमाणे.

1) पुर्वेस : प्रकाश घारसे यांचे बांधलेली झाडाची झुडपे.
2) पश्चिमेस : अर्धापुरकडे जाणारा डांबरी रोड.
3) दक्षिणेस : नांदेडकडे जाणारा डांबरी रोड (वसमतफाटा)
4) उत्तरेस : हिंगोलीकडे जाणारा रोड. (पाटी)

मला प्रवाल्या घटनास्थळाच्या चतुःसीमा मजुर सदरचा पंचनामा मजुर पंचासमक्ष दिसत्या परिस्थितीप्रमाणे स्वच्छ सुर्यप्रकाशात केला असून त्यावर माझ्या व पंचाच्या सह्या आहेत.

अक्षांश - 19° 11' 13"
रेखांश - 77° 20' 11"

FORM - VI

9.घटनास्थळाचा नकाशा :-

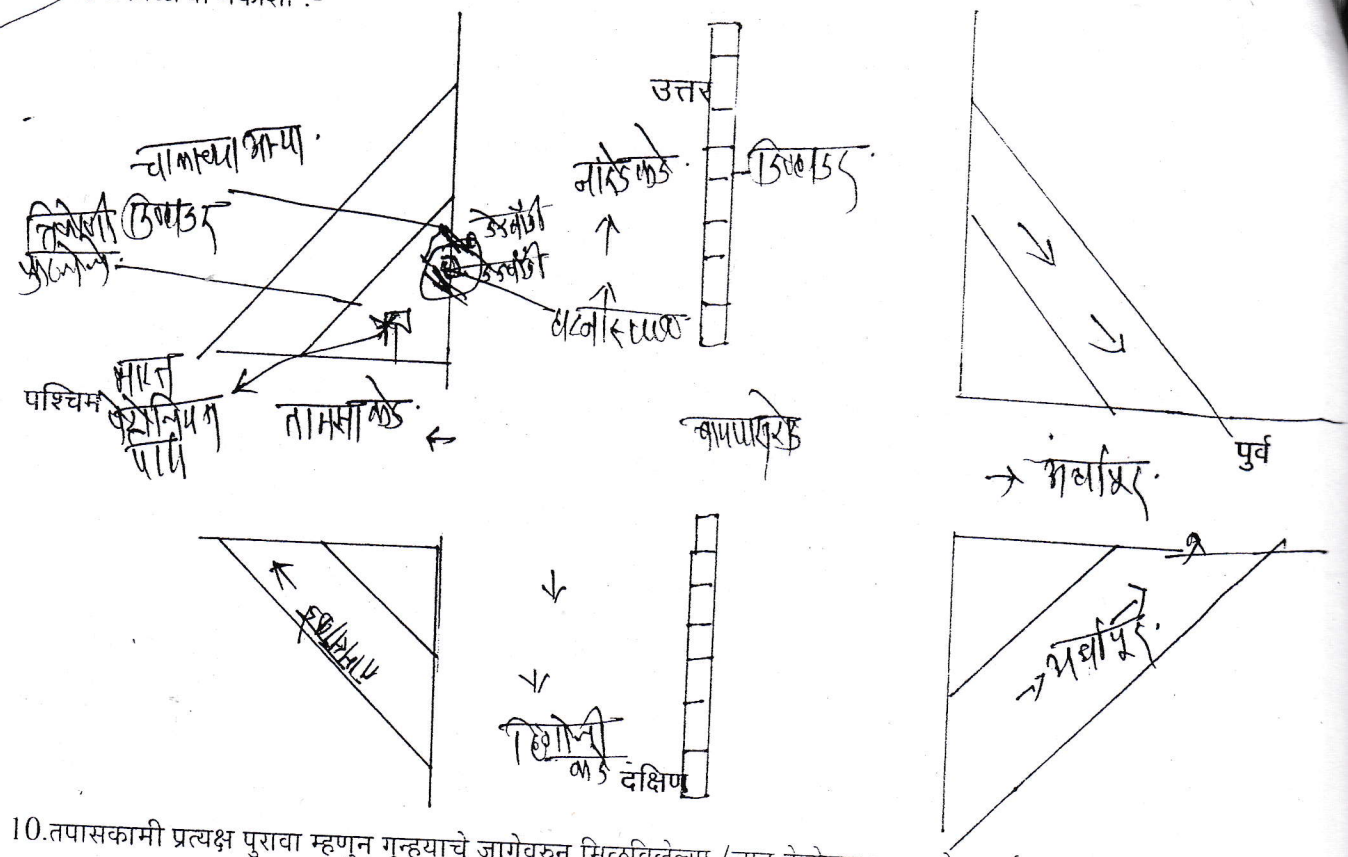

10.तपासकामी प्रत्यक्ष पुरावा म्हणुन गुन्हयाचे जागेवरुन मिळविलेल्या /जप्त केलेल्या मालमत्तेच वर्णन :-

10,00,000=00 एक लाख रुपयाचा एक निळ्या व पांढऱ्या कलरच्या पुर्वपरी कालेपा महिंद्रा ऑटोरिक्षा व त्यामध्ये बसलेला 12 वर्षाच्या एक मुलाचा असून त्याचा पासिंग क्र. MH 35 K 3690 असा अ.वा.वि.भ.

11.घटनास्थळ पंचनाम्याची दिनांक 03/10/2019 वेळ 12:00 ते 12:40 वार

12. पंचाची नांवे व संपुर्ण पत्ता आणि सही :-

1) व्यंकटी तुकाराम शिंदे वय 40 वर्षे व्यवसाय शेती
रा. तिरकसवाडी ता. मुदखेड जि. नांदेड मो. 9823109137.

2) पुंडाजी हिरामण येळगे वय 40 वर्षे व्यवसाय शेती
रा. तिरकसवाडी ता. मुदखेड जि. नांदेड मो 7776990651

तपासीक अधिकारी सही :-

दिनांक 03/10/19

नाव कपील मु. आगलावे

पदनाम पोलीस उपनिरीक्षक

पोलीस ठाणे पो.स्टे. अर्धापूर जि. नांदेड

CJPN (O-127)–9-2008–5,00,000 Bks./4 lvs.--PA4*
G. R., G. D., No. 733/33, dated 16-6-41 and
G. R., H. and L. G. D., No. 733/33, dated 11-12-47,
wide Surgeon General with the Govt. of Maharashtra, Bombay's
Letter No. FRM/1462/19357/1, dated 4-7-62.]

मा.क्र./प्राआकेंद्र/438/आरखी/
शासकीय प्राथमिक आ.केंद्र अर्धापूर
ता.अर्धापूर, जि.नांदेड
दिनांक 02/11/2019

Memorandum of a post-mortem examination held at Primary Health Centre Ardhapur Dispensary Hospital

on the dead body of BALAJI GUNAJI KOKATE of Village / City TIRKASWADI

Taluka MUDKHED, District NANDED, by Dr. R.S. MORE

I. General Particulars—

1. (a) By whom was the corpse sent? — PSI Mr. K. M. AAGLAVE police station Ardhapur

(b) Name of place from which sent. — Brought dead by Highway Ambulance Ardhapur on 2/10/2019 at 2:50 pm

(c) Distance of place from which sent.

2. By whom was the corpse brought? — ASI Mr. G. N. PANPATIE police station Ardhapur

3. By whom identified?

4. The date, hour and minute of its receipt. — 02/10/2019 4:05 pm

(a) The date, hour and minute of beginning post-mortem examination. — 02/10/2019 4:10 pm

(b) The date, hour and minute of ending post-mortem examination. — 02/10/2019 5:10 pm

5. Substance of accompanying Report from Police Officer or Magistrate, together with the date of death if known. Supposed cause of death or reason, for examination. — As per police inquest to know exact cause of death, post-mortem examination is requested.

6. If not examined at Dispensary or Hospital—

(a) Name of place where examined.

(b) Distance from Dispensary or Hospital—

(c) Reason why the body was not sent to the Dispensary or Hospital.

NOT APPLICABLE

II. External Examination—

7. Sex, apparent age, race or caste. — Male, 42 years, Hindu.

Description of clothes and of ornaments on the body. — White colored shirt, Black brown colored pant, maroon colored underwear, red colored Kardora around waist with key tied to it, beaded string around neck.

8. *Condition of the clothes—* Whether wet with water, stained with blood or soiled with vomit or foecal matter. — Shirt stained with blood and mud, pant torn at knee joint

9. Special marks on the skin such at scars, tattooing etc., any malformations peculiarities, or other marks of identification. State of the teeth. — Body duly identified by the investigating officer. Identification mark - Mole over chest

In newly born infants, the length and (if possible), the weight of the body to be recorded together with the state of the hair, nails and umbilical cord, its length, whether placenta is attached or not, if present, its size and condition. — Not Applicable

15. Injuries to external genitals. Indication of purging

Intact, no injury.
No purging.

16. *Position of limbs*— Especially of arms and of fingers in suspected drowning the presence or absence of sand or earth within the nails or on the skin of hands and feet.

Body in supine position with
1> Right upper extremity adducted at shoulder joint, extend at elbow joint & flexion at interphalangeal joints.
2> Left upper extremity adducted at shoulder joint, extend at elbow joint. forehand abducted with flexion at inter-phalangeal joints
3> Both lower extremities straight with laterally rotated feet.

17. *Surface wounds and injuries*—Their nature, position, dimensions (measured) and directions to be accurately stated-their probable age and causes to be noted.

If bruises be present what is the condition of the subcutaneous tissues ?

(N.B.—(When injuries are numerous and cannot be mentioned within the space available they should be mentioned on a separate paper which should be signed).

(1) CLW over Left parieto-temporal area 4x2x2cm bone deep oblique, irregular margin.
(2) Extensive crush injury seen over right axilla exposing underlying muscles and bone with irregular shape & size.
(3) Extensive crush injury seen over left popliteal area involving upper calf exposing underlying muscles and bone, irregular in shape and size.
(4) Extensive crush injury seen over medial side of left scrotum and left inguinal area exposing underlying muscles & bone, irregular in shape & size.
(5) Extensive crush injury over left foot exposing underlying muscles & bone irregular in shape & size. Skin over foot hanging.
(6) Extensive print abrasion over right Hypochondrial area 20x10 cm.
(7) Print abrasion over Left scapular area 5x10cm
(8) Print abrasion over left lumbar area 6x5cm.
(9) Print abrasion over Left bicep 10x5 cm.
(10) Print abrasion over left tricep 3x4cm
(11) Abrasion over left elbow 2x2cm
(12) Print abrasion over Left thigh anterior aspect 10x3

Above injuries caused in Road Traffic Accident.

18. Other injuries discovered by external examination or palpation as fractures etc.

(1) fracture of right forehand in midarea.
(2) fracture of Left upper tibia.

(a) Can you say definitely that the injuries shown against serial Nos. 17 and 18 are ante mortem injuries ?

Yes, injuries shown against serial Nos. 17 and 18 are ante-mortem injuries.

15. Injuries to external genitals. Indication of purging

Intact, no injury.
No purging.

16. *Position of limbs*— Especially of arms and of fingers in suspected drowning the presence or absence of sand or earth within the nails or on the skin of hands and feet.

Body in supine position with
1> Right upper extremity adducted at shoulder joint, extend at elbow joint & flexion at interphalangeal joints.
2> Left upper extremity adducted at shoulder joint, extend at elbow joint. forehand abducted with flexion at interphalangeal joints
3> Both lower extremities straight with laterally rotated feet.

17. *Surface wounds and injuries*—Their nature, position, dimensions (measured) and directions to be accurately stated-their probable age and causes to be noted.

(1) CLW over Left parieto-temporal area 4x2x2cm bonedee oblique, irregular margin.
(2) Extensive crush injury seen over right axilla exposing underlying muscles and bone with irregular shape & size.
(3) Extensive crush injury seen over Left popliteal area involving upper calf exposing underlying muscles and bone, irregular in shape and size.
(4) Extensive crush injury seen over medial side of Left scrotum and Left inguinal area exposing underlying muscles & bone, irregular in shape & size.
(5) Extensive crush injury over Left foot exposing underlying muscles & bone irregular in shape & size. skin over foot hanging.

If bruises be present what is the condition of the subcutaneous tissues ?

(6) Extensive print abrasion over right Hypochondrial area 20x10 cm.
(7) Print abrasion over Left scapular area 5x10cm
(8) Print abrasion over Left Lumbar area 6x5cm.
(9) Print abrasion over Left bicep 10x5cm.
(10) Print abrasion over Left tricep 3x4cm
(11) Abrasion over left elbow 2x2cm
(12) Print abrasion over Left thigh anterior aspect 10x3

(*N.B.*—(When injuries are numerous and cannot be mentioned within the space available they should be mentioned on a separate paper which should be signed).

Above injuries caused in Road Traffic Accident.

18. Other injuries discovered by external examination or palpation as fractures etc.

(1) fracture of right forehand in midarea.
(2) fracture of Left upper tibia.

(a) Can you say definitely that the injuries shown against serial Nos. 17 and 18 are ante mortem injuries ?

Yes. injuries shown against serial Nos. 17 and 18 are ante-mortem injuries.

Condition of body.— Whether well-nourished, thin or emaciated, warm or cold.

Average nourished and built.
Cold body.

11. *Rigar Mortis*—Well-marked, slight or absent; whether present in the whole body or part only.

Rigar Mortis present upto neck area
Rigar Mortis absent lower down.

12. Extent and signs of decomposition, presence post-mortem lividity of buttocks, loins, back and thighs or any other part. Whether bullae present and the nature of their contained fluid. Condition of the cuticle.

No signs of decomposition seen.
Post-Mortem lividity absent.

13. *Features*—Whether natural or swollen, state of eyes, position of tongue : nature of fluid (if any) oozing from mouth, nostrils or ears.

features natural
Both Eyes closed, Tongue within oral cavity,
Mouth partly opened, Bleeding from both nostrils
Bleeding from left ear.
No ooing from mouth.

14. *Condition of skin*—Marks of blood etc. In suspected drowning the presence or absence of cutes anserina to be noted.

Face smeared with blood.

21. Abdomen—

Walls	Intact
Peritoneum	Intact, no injury.
Cavity	Intact, no injury. No blood or free fluid present in peritoneal cavity.
Bucal Cavity, teeth, tongue and Pharynx.	Intact, no injury.
Desophagus	Intact, no injury.
Stomach and its contents	Intact, distended with semidigested food, no peculiar smell perceived, mucosa - pale.
Small intestine and its contents.	Intact, distended with gases.
Large intestine and its contents.	Intact, distended with gases and feces.
Liver (with weight) and gall bladder.	Intact, no injury, pale
Pancreas and Suprarenals	Intact, no injury.
Spleen with weight	Intact, no injury, pale.
Kidneys with weight	Intact, no injury, pale
Bladder	Intact, no injury, empty.
Organs of generations	No abnormality detected.
Additional remarks with where possible, medical officer's deduction from the state of the contents of the stomach as to time of death and last meal.	As per stomach content time of death is within 4 to 6 hours of his last meal consumed.
State which viscera (if any) have been retained for chemical examination and also quote the numbers on the bottles containing the same.	Viscera not retained for chemical examination

III. Internal Examination—

19. *Head—*

(i) Injuries under the scalp, their nature. — Underscalp haematoma present over left parieto-temporal area 10x6 cm.

(ii) ***Skull***—Vault and base-describe fractures, their sites, dimensions, directions, etc. — Intact, no fracture

(iii) ***Brain***—The appearance of its coverings, size, weight and general condition of the organ itself and any abnormality found in its examination to be carefully noted (weight M. 3 grams F. 2.75 grams). — - Subdural haemorrhage present over left parieto-temporal area
- Patchy subarachnoid hemorrhage present over right parietal area.
- Brain matter congested, oedematous with blood clot present in corpus callosum area.

20. *Thorax—*

(a) Walls, ribs, cartilages — Fracture of ribs on right thoracic cage in 2, 3, 4, 5, 6 ribs
Fracture of ribs on left thoracic cage in 6, 7, 8, 9 ribs

(b) Pleura — Pleura disrupted due to inward pointing ends of fractured ribs over both sides

(c) Larynx, Trachea and Bronchi. — Intact, no injury.

(d) Right Lung — Intact, No injury

(e) Left Lung — Intact, no injury.

(f) Pericardium — Intact, no injury
No abnormal collection in pericardium

(g) Heart with weight — Intact, no injury.

(h) Large vessels — Intact, no injury.

(j) Additional remarks. — Nil.

22. *Spine and Spinal Cord—

Intact

Opinion as to the cause
probable cause of death.

" HAEMORRHAGIC SHOCK due to injury to vital orgain Brain with POLYTRAUMA in Road Traffic Accident".

Dr. R. S. MORE
Medical Officer
Primary Health Centre Ardhapur.
(Signature)

Dated 25/10/2019 200

*The Spinal Cord need not be examined unless there are any indications of disease, Strychnia poisoning or injury.

Note—The report must be written and signed immediately after the examination. Medical Officers will at once despatch a duplicate copy to the Civil Surgeon of their district for record in his office.

Great care should be taken not to cut the viscera before they have been inspected *in situ.*

P. M. No. 21/2019 200

Place Dispensary / Civil Hospital Primary Health centre Ardhapur 200 2019.

Forwarded to the Police Sub-Inspector Police station Ardhapur

for information with reference to his No. of 200

2. Viscera has been preserved. It may please be stated *Immediately* whether examination by the Chemical Analyser is necessary or it is to be destroyed.

Medical Officer
Civil Surgeon or M. M. S. Officer

Copy forwarded with compliments to the Civil Surgeon, for information.

M. M. S. Officer

Seen and examined by the Civil Surgeon,

200 on

Remarks of the Civil Surgeon, (if any)

Civil Surgeon

C. M. 67 e.

CJPN (O-127)–9-2008–5,00,000 Bks./4 lvs.--PA4*
G. R., G. D., No. 733/33, dated 16-6-41 and
G. R., and L. G. D., No. 733/33, dated 11-12-47,
vide Surgeon General with the Govt. of Maharashtra, Bombay's
Letter No. FRM/1462/19357/1, dated 4-7-62.]

MLPM NO. 941/19

Memorandum of a post-mortem examination held at Dr. S.C. GMC Nanded 02/10/19 Dispensary Hospital

on the dead body of Pundlik Damaji Shinde of Village / City Tirakaswadi

Taluka Mudhkhed, District Nanded by Dr. S.B. Madewad, Dr. A.A. Chavan

I. General Particulars—

1. (a) By whom was the corpse sent? N.P.C. W.K. Kamble B.no. 2801 Nanded Gramin Police station

(b) Name of place from which sent. casualty

(c) Distance of place from which sent. Dr. S.C. GMC Nanded

2. By whom was the corpse brought? P.C. Jokhande B.no. 3327 Nanded Gramin Police station

3. By whom identified?

4. The date, hour and minute of its receipt. 02/10/19 04:25 pm

(a) The date, hour and minute of beginning post-mortem examination. 02/10/19 04:40 pm

(b) The date, hour and minute of ending post-mortem examination. 02/10/19 05:40 pm

5. Substance of accompanying Report from Police Officer or Magistrate, with the date of

As per police inquest and requisition, deceased had history road traffic accident on 02/10/19 at 13:30 hr for that he was brought to Dr. S.C. GMC Nanded, doctors on duty declared brought dead on 02/10/19 at 15:10 hr

Cause of death: Road traffic accide

6. If not examined at Dispensary or Hospital—

(a) Name of place where examined.

(b) Distance from Dispensary or Hospital—

(c) Reason why the body was not sent to the Dispensary or Hospital.

not applicable

II. External Examination—

7. Sex, apparent age, race or caste.

Male, 55 years

Description of clothes and of ornaments on the body.

white coloured dhoti
white coloured shirt
white sando baniyan
white coloured kaccha
Red waist thread

8. *Condition of the clothes*— Whether wet with water, stained with blood or soiled with vomit or foecal matter.

Dry intact, handed over PC on duty

9. Special marks on the skin such at scars, tattooing etc., any malformations peculiarities, or other marks of identification. State of the teeth.

Body identified by investigating officer on duty,
teeth-16/16

In newly born infants, the length and (if possible), the weight of the body to be recorded together with the state of the hair, nails and umbilical cord, its length, whether placenta is attached or not, if present, its size and condition.

not applicable

10. ***Condition of body***—Whether well-nourished, thin or emaciated, warm or cold.

Average built / cold

11. ***Rigar Mortis***—Well-marked, slight or absent; whether present in the whole body or part only.

Partially present on whole body parts

12. Extent and signs of decomposition, presence post-mortem lividity of buttocks, loins, back and thighs or any other part. Whether bullae present and the nature of their contained fluid. Condition of the cuticle.

No signs of decomposition
Postmortem lividity present on posterior aspect of body except pressure area
not fixed

13. ***Features***—Whether natural or swollen, state of eyes, position of tongue : nature of fluid (if any) oozing from mouth, nostrils or ears.

Features : natural
eyes - closed
mouth - closed
tongue - inside the mouth
oozing of blood from left nostril and left angle of mouth

14. ***Condition of skin***—Marks of blood etc. In suspected drowning the presence or absence of cutes anserina to be noted.

Dry, Pale

15. Injuries to external genitals. Indication of purging.

No injury to external genitals
Purging in the form of semen present

16. ***Position of limbs***— Especially of arms and of fingers in suspected drowning the presence or absence of sand or earth within the nails or on the skin of hands and feet.

Straight

17. ***Surface wounds and injuries***—Their nature, position, dimensions (measured) and directions to be accurately stated-their probable age and causes to be noted.

① lacerated wound present over left temporal region of size 3cm x 0.5cm x tissue deep, red
② lacerated wound present over left ear pinna on upper side of size 1cm x 0.5cm x tissue deep, red
③ multiple abrasions present over right cheeck of varying size from 1cm x 0.5cm to 2 x 0.5cm, red
④ Contused abrasion present below ~~left~~ right nostril of size 2cm x 1cm, red
⑤ Graze abrasion present over tip of right shoulder on posterior aspect of size 5cm x 2cm directed upwards, red
⑥ Contused abrasion present over right elbow on lateral aspect of size 4cm x 2cm, red
⑦ contused abrasion present over right knee on lateral aspect of size 3cm x 2cm red.
⑧ 2 circular imprint abrasions present over left thigh on upper part seperated about 4cm apart from each other of size 2cm in diameter, red
⑨ lacerated wound present over mid part of left thigh on lateral aspect of size 6cm x 0.5cm x tissue deep, red
⑩ Abrasion present over left knee on lateral aspect of size 2cm x 0.5cm red.

If bruises be present what is the condition of the subcutaneous tissues ?

(*N.B.*—(When injuries are numerous and cannot be mentioned within the space available they should be mentioned on a separate paper which should be signed).

18. Other injuries discovered by external examination or palpation as fractures etc.

(a) Can you say definitely

II. Internal Examination—

19. *Head*—

(i) Injuries under the scalp, their nature.

undorscalp haematoma present over both temperal region and occipital region

(ii) *Skull*—Vault and base-describe fractures, their sites, dimensions, directions, etc.

Fracture present over sutural line at right temporoparietal region extending upto left temporoparietal region
fractures margins irregular infiltrate with blood.

(iii) *Brain*—The appearance of its coverings, size, weight and general condition of the organ itself and any abnormality found in its examination to be carefully noted (weight M. 3 grams F. 2.75 grams).

Meninges : Intact, congested.
Brain : multiple contusions present over both cerebral cortex & cerebellum at places.

20. *Thorax*—

(a) Walls, ribs, cartilages

linear fracture present over left 2nd, 3rd, 4th ribs at posterior axillary line, fractures margins irregular and infiltrate with blood. Haemorrhages present in surrounding intercostal muscles

(b) Pleura

Intact no fluid

(c) Larynx, Trachea and Bronchi.

Intact, no foreign body

(d) Right Lung

(e) Left Lung

Intact, congested

(f) Pericardium

Intact

(g) Heart with weight

(h) Large vessels

Intact, blood and blood clots present

15. Injuries to external genitals. Indication of purging.

No injury to external genitals
Purging in the form of semen present

16. ***Position of limbs***—Especially of arms and of fingers in suspected drowning the presence or absence of sand or earth within the nails or on the skin of hands and feet.

Straight

17. ***Surface wounds and injuries***—Their nature, position, dimensions (measured) and directions to be accurately stated-their probable age and causes to be noted.

① lacerated wound present over left temporal region of size 3cmx0.5cmxtissue deep, red
② lacerated wound present over left ear pinna on upper side of size 1cmx0.5cmxtissue deep, red
③ multiple abrasions present over right cheek of varying size from 1cmx0.5cm to 2x0.5cm, red
④ contused abrasion present below ~~left~~ right nostril of size 2cmx1cm, red (AR Moran)
⑤ Graze abrasion present over tip of right shoulder on posterior aspect of size 5cmx2cm directed upwards, red
⑥ Contused abrasion present over right elbow on lateral aspect of size 4cmx2cm, red
⑦ contused abrasion present over right knee on lateral aspect of size 3cmx2cm, red.
⑧ 2 circular imprint abrasions present over left thigh on upper part seperated about 4cm apart from each other of size 2cm in diameter, red
⑨ lacerated wound present over mid part of left thigh on lateral aspect of size 6cmx0.5cmx tissue deep, red
⑩ Abrasion present over left knee on lateral aspect of size 2cmx0.5cm, red.

If bruises be present what is the condition of the subcutaneous tissues ?

(*N.B.*—(When injuries are numerous and cannot be mentioned within the space available they should be mentioned on a separate paper which should be signed).

18. Other injuries discovered by external examination or palpation as fractures etc.

(a) Can you say definitely that the injuries shown against serial Nos. 17,

Yes, Antemortem

II. Internal Examination—

19. *Head*—

(i) Injuries under the scalp, their nature.

undorscalp haematoma present over both temporal region and occipital region

(ii) *Skull*—Vault and base-describe fractures, their sites, dimensions, directions, etc.

Fracture present over sutural line of right temporoparietal region extending up to left temporoparietal region
fractures margins irregular infiltrate with blood.

(iii) *Brain*—The appearance of its coverings, size, weight and general condition of the organ itself and any abnormality found in its examination to be carefully noted (weight M. 3 grams F. 2.75 grams).

Menings : Intact, congested.
Brain : multiple contusions present over both cerebral cortex & cerebellum at places.

20. *Thorax*—

(a) Walls, ribs, cartilages

linear fracture present over left 2nd, 3rd, 4th ribs at posterior axillary line, fractures margins irregular and infiltrate with blood. Haemorrhages present in surrounding intercoastal muscles

(b) Pleura

Intact no fluid

(c) Larynx, Trachea and Bronchi.

Intact, no foreign body

(d) Right Lung

(e) Left Lung

Intact, congested

(f) Pericardium

Intact

(g) Heart with weight

(h) Large vessels

Intact, blood and blood clots present

21. ***Abdomen—***

Walls	Intact
Peritoneum	Intact, no free fluid
Cavity	
Bucal Cavity, teeth, tongue and Pharynx.	Intact, no foreign body
Oesophagus	Intact
Stomach and its contents	Intact, about 800ml yellowish coloured fluid with semidigested food material present no abnormal smell perceived
Small intestine and its contents.	Intact, partly loaded with faeces and gases
Large intestine and its contents.	
Liver (with weight) and gall bladder	Intact, congested
Pancreas and Suprarenals	
Spleen with weight	Intact, congested
Kidneys with weight	
Bladder	Intact, empty
Organs of generations	Intact
Additional remarks with where possible, medical officer's deduction from the state of the contents of the stomach as to time of death and last meal.	Nil
State which viscera (if any) have been retained for chemical examination and also quote the numbers on the bottles containing the same	Viscera not preserved

22. *Spine and Spinal Cord—

Intact, not opened

Opinion as to the cause probable cause of death.

"Head injury"

(Dr. S.B. Madewad)
Asst. Professor
Dept. Of Forensic Medicine & Toxicology
Dr. Shankarrao Chavan Govt.
Medical College, Nanded.

(Dr. A.A. Chavan)
Resident
Dept. of Forensic Medicine
Dr. S.C.G.M.C. Vishnupuri
Nanded-431606

(*Signature*)

Dated 02/10/19 200

*The Spinal Cord need not be examined unless there are any indications of disease, Strychnia poisoning or injury.

Note—The report must be written and signed immediately after the examination. Medical Officers will at once despatch a duplicate copy to the Civil Surgeon of their district for record in his office.

...cut the viscera before they have been inspected *in situ*.

MLPM No. 941/19

02/10/19

8

No. 200

Place Dispensary / Civil Hospital Dr. S.C.G.M.C Nanded 200

Forwarded to the Police Sub-Inspector Nanded Gramin Police station

for information with reference to his No. FMLC/4257/19 of 200

2. Viscera has been preserved. It may please be stated ***Immediately*** whether examination by the Chemical Analyser is necessary or it is to be destroyed.

A. A. Chavan
(Dr. A. A. Chavan)
Resident
Dept. of Forensic Medicine
Dr. S.C.G.M.C. Vishnupuri
Nanded-431606

(Dr. S. B. Madewad)
Asst. Professor
Dept. Of Forensic Medicine & Toxicology
Dr. Shankarrao Chavan Govt.
Medical College, Nanded.

Civil Surgeon or M. M. S. Officer

Copy forwarded with compliments to the Civil Surgeon. for information.

M. M. S. Officer

Seen and examined by the Civil Surgeon, on

200

Remarks of the Civil Surgeon, (if any)

मूळ प्रत मिळाली ----------

प्रेषणाऱ्याचे नांव / हद्दा ----------